Erkrankungen der Vulva

Dr. med. Isabella Terrani
Leitendeärztin Ospedale Regionale di Lugano
8. Pflegekongress für Gynäkologie

Stadt Zürich
Stadtspital Triemli
eoc

Erkrankungen der Vulva

A. Besonderheiten der Vulva
B. Klinische Fälle

Anatomie

- Erhöhte Temperatur
- Feuchtigkeit
- Sekretesposition
- Mechanische Irritation

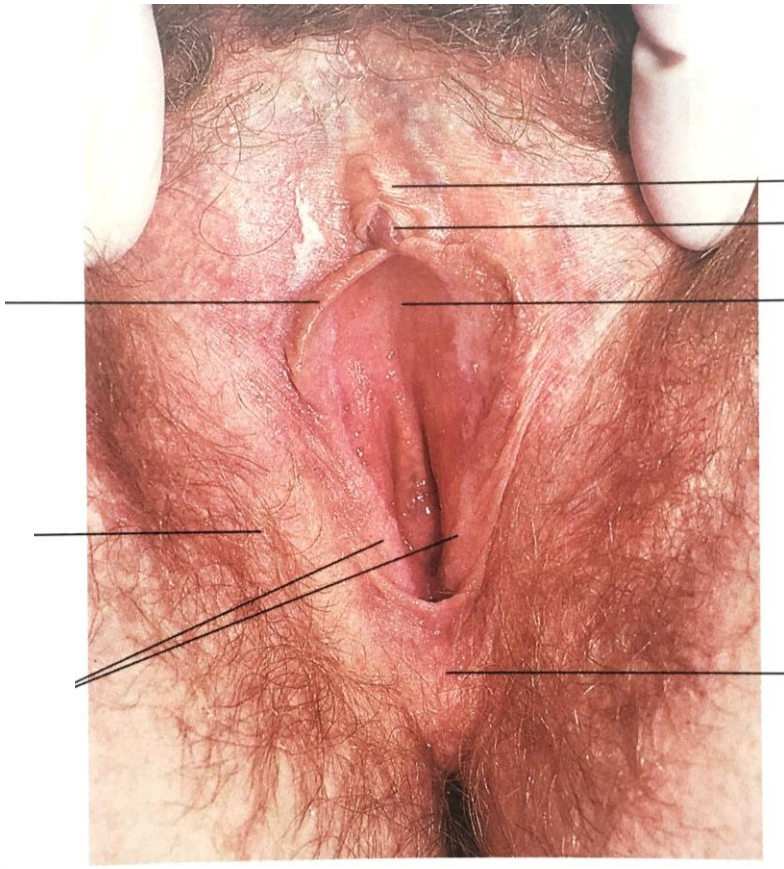

FIG. 1-1. Normal vulva.

Edwards L, Lynch PJ. Genital Dermatology Atlas (2° edition). Wolters Kluwer, 2011

Labia minora

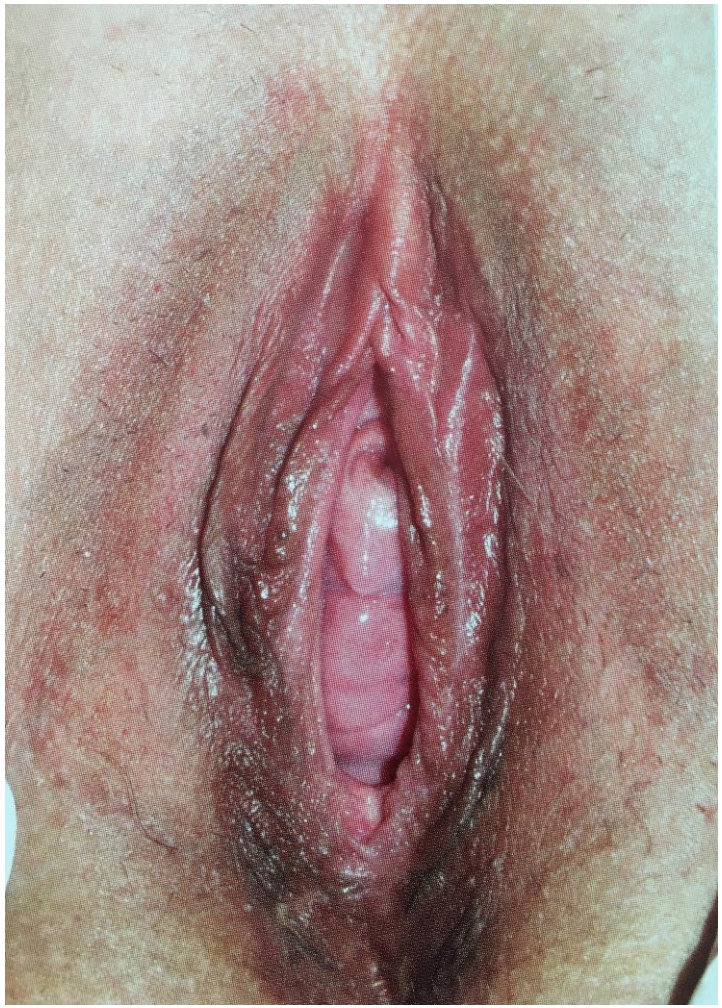

Edwards L, Lynch PJ. Genital Dermatology Atlas (2° edition). Wolters Kluwer, 2011

Labia minora

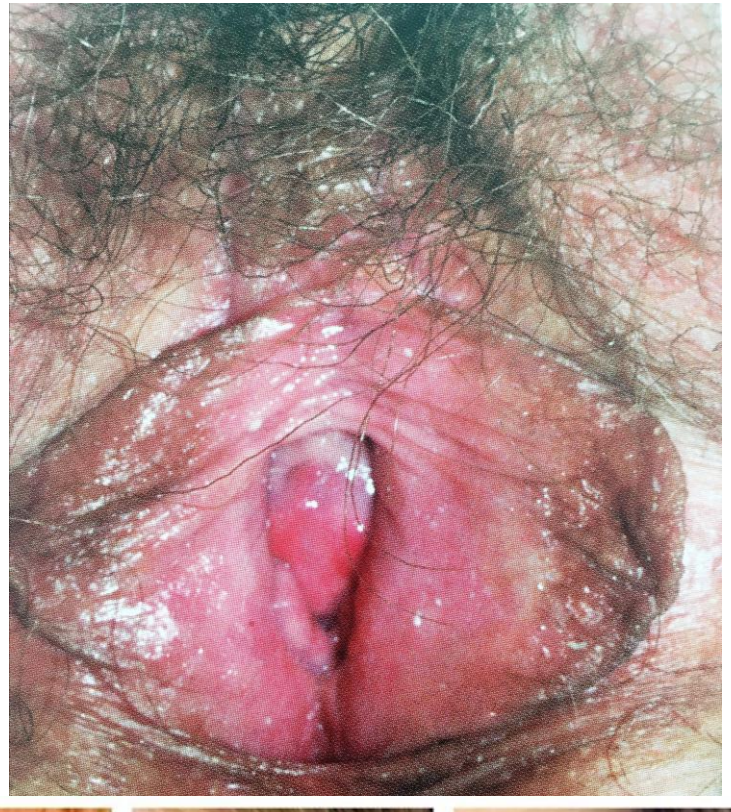

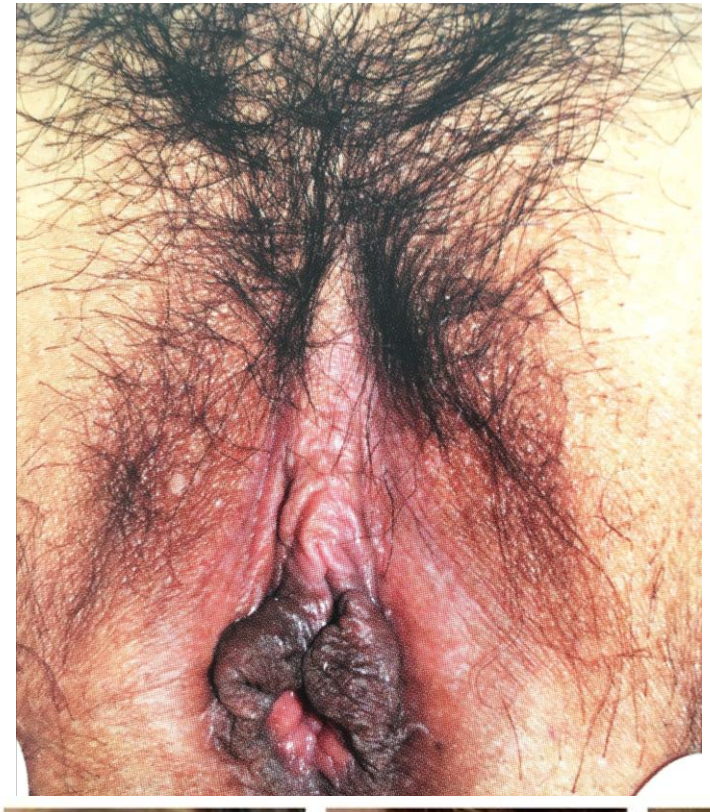

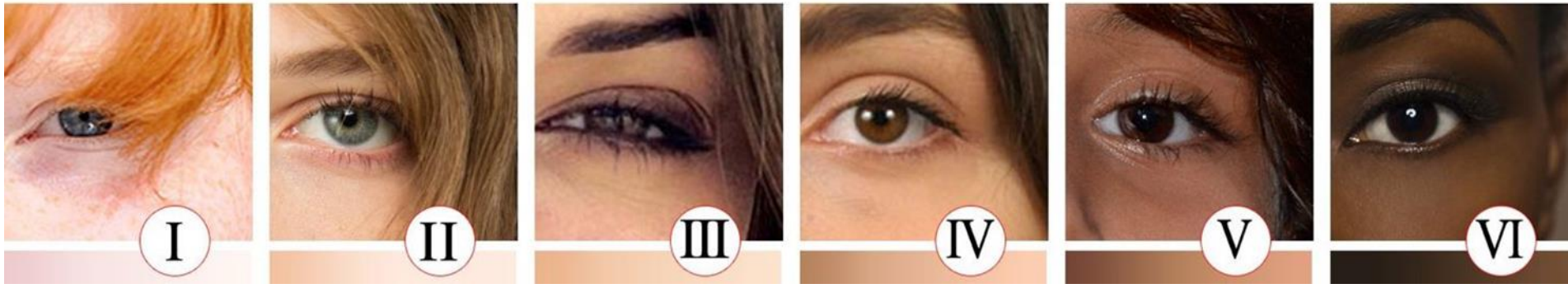

Anatomie

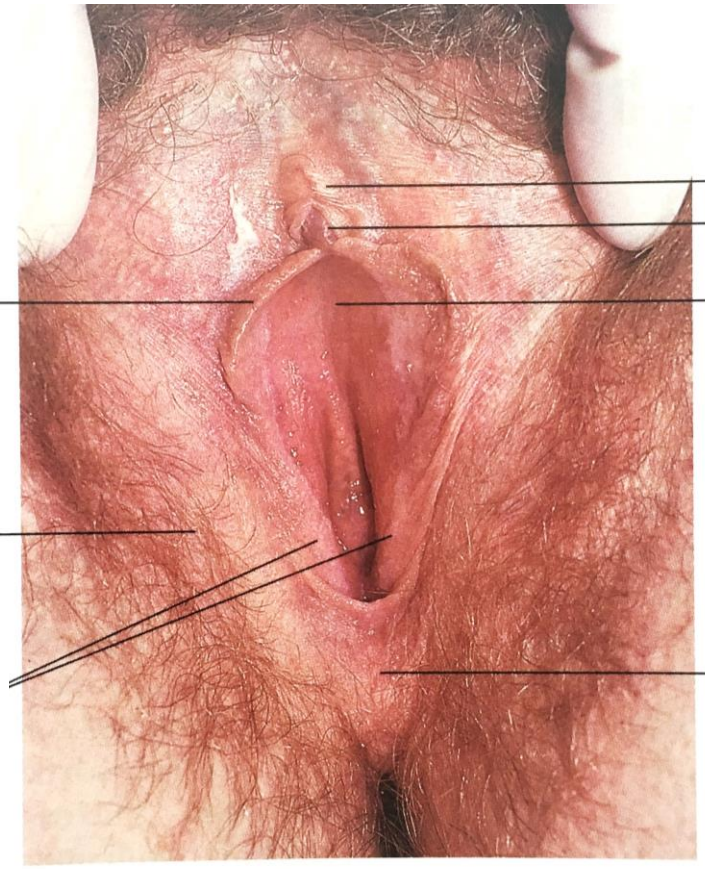

FIG. 1-1. Normal vulva.

Edwards L, Lynch PJ. Genital Dermatology Atlas (2° edition). Wolters Kluwer, 2011

Anatomie

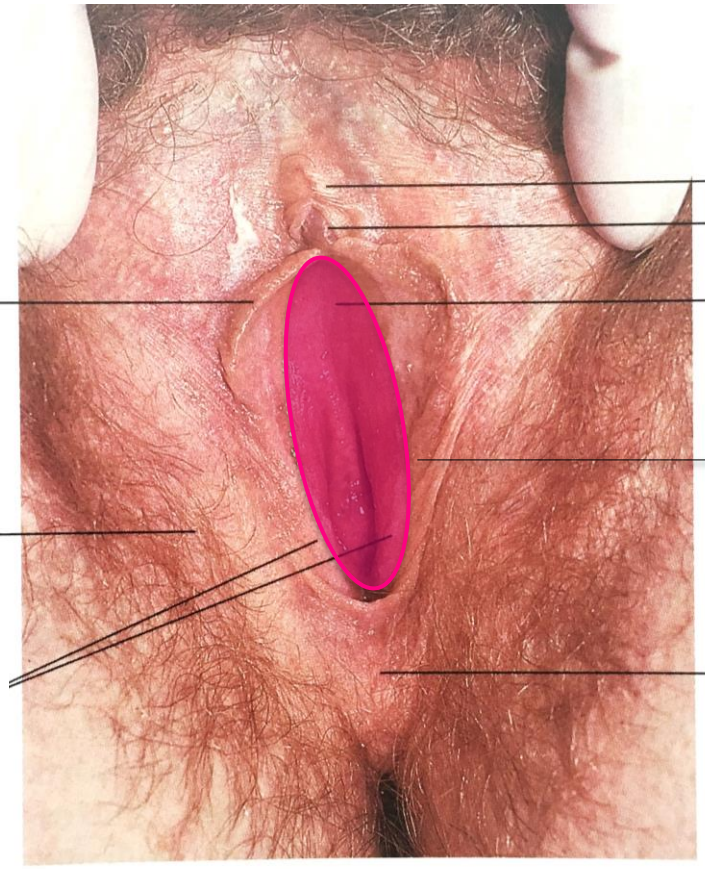

FIG. 1-1. Normal vulva.

Edwards L, Lynch PJ. Genital Dermatology Atlas (2° edition). Wolters Kluwer, 2011

Vestibulum vaginae

VULVA: Verhornendes Plattenepithel (mit Apokrinen Drüsen, Talgdrüsen und Haarfollikel)

VESTIBULUM + LABIA MINORA INNENSEITE: nicht verhornendes Plattenepithel

Edwards L, Lynch PJ. Genital Dermatology Atlas (2° edition). Wolters Kluwer, 2011

Edwards L, Lynch PJ. Genital Dermatology Atlas (2° edition). Wolters Kluwer, 2011

Fordyce Drüsen

Edwards L, Lynch PJ. Genital Dermatology Atlas (2° edition). Wolters Kluwer, 2011

Diagnose?

Edwards L, Lynch PJ. Genital Dermatology Atlas (2° edition). Wolters Kluwer, 2011

Vestibular papillomatosis

Edwards L, Lynch PJ. Genital Dermatology Atlas (2° edition). Wolters Kluwer, 2011

Edwards L, Lynch PJ. Genital Dermatology Atlas (2° edition). Wolters Kluwer, 2011

Vestibular papillomatosis vs Condylomata acuminata (HPV)

B. Klinische Fälle

Juckreiz

Skabies

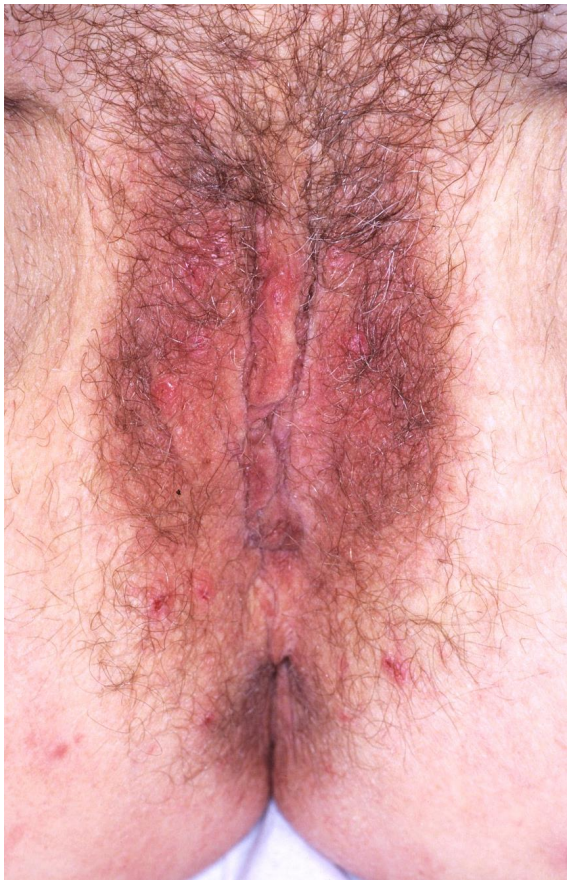

Psoriasis inversa

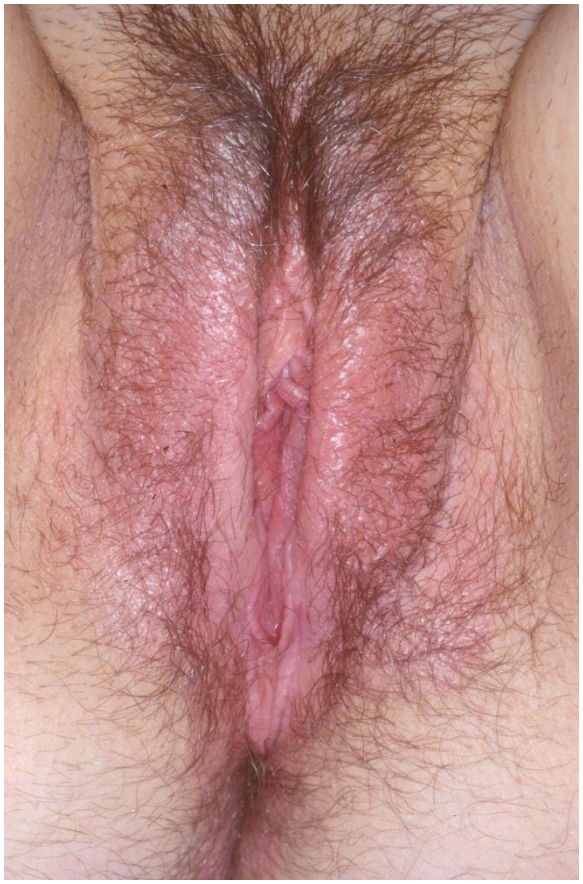

Seborrhoisches Ekzem

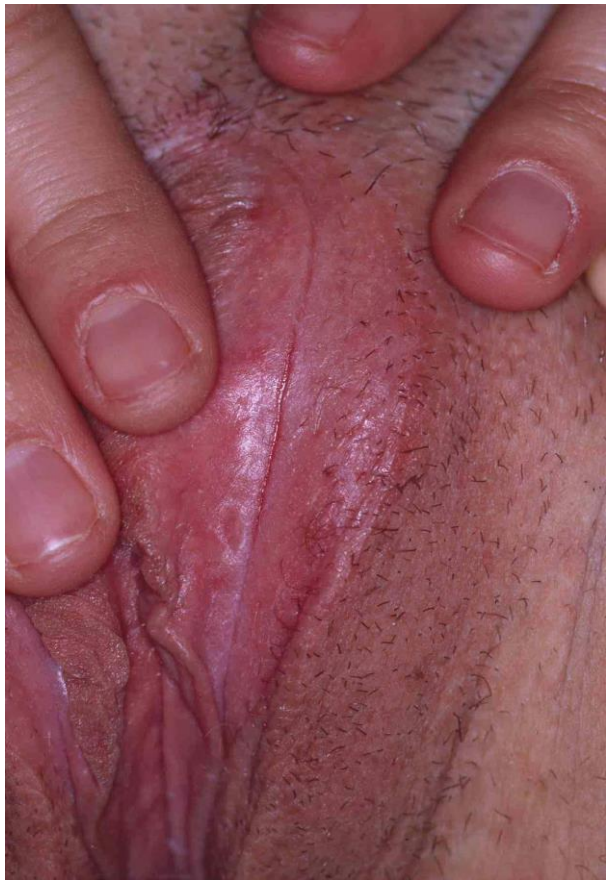

Mit freundlicher Genehmigung von Prof. Dr. med. S. Lautenschlager

Skabies

Fox G. Diagnosis of scabies by dermscopy. BMJ Feb 2009

Stadt Zürich
Stadtspital Triemli

eoc

Psoriasis

- Häufige, T-Zell vermittelte chronische entzündliche Erkrankung mit starke genetische Basis, die charakterisiert ist durch:
  - scharf begrenzte
  - erythro-squamöse Plaques
  - v.a. an Gelenkstreckseiten und Skalp

- Ausgeprägte Variabilität bezüglich:
  - Krankheitsverlauf, Ausdehnung und Morphologie

Psoriasis Epidemiologie

Prävalenz der Psoriasisi der Kaukasische Population?

A. 0.5 %
B. 1%
C. 2%
D. 10%

Fitzpatrick's, Dermatology, 8th edition.

Psoriasis Epidemiologie

Prävalenz der Psoriasisi der Kaukasische Population?

A. 0.5 %
B. 1%
C. 2%
D. 10%

Fitzpatrick's, Dermatology, 8th edition.

Psoriasis vulgaris

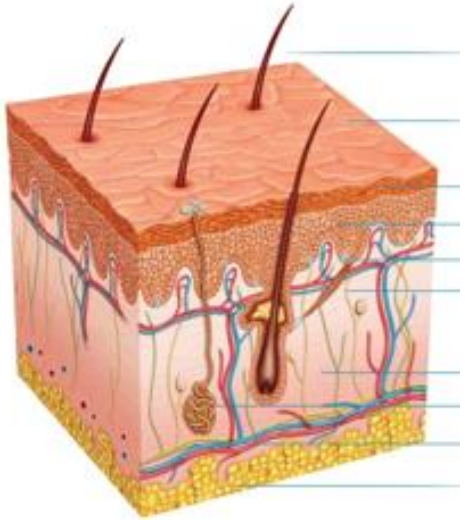

Keratinozyt

Systemische Erkrankung

Psoriasis inversa vs Psoriasis vulgaris

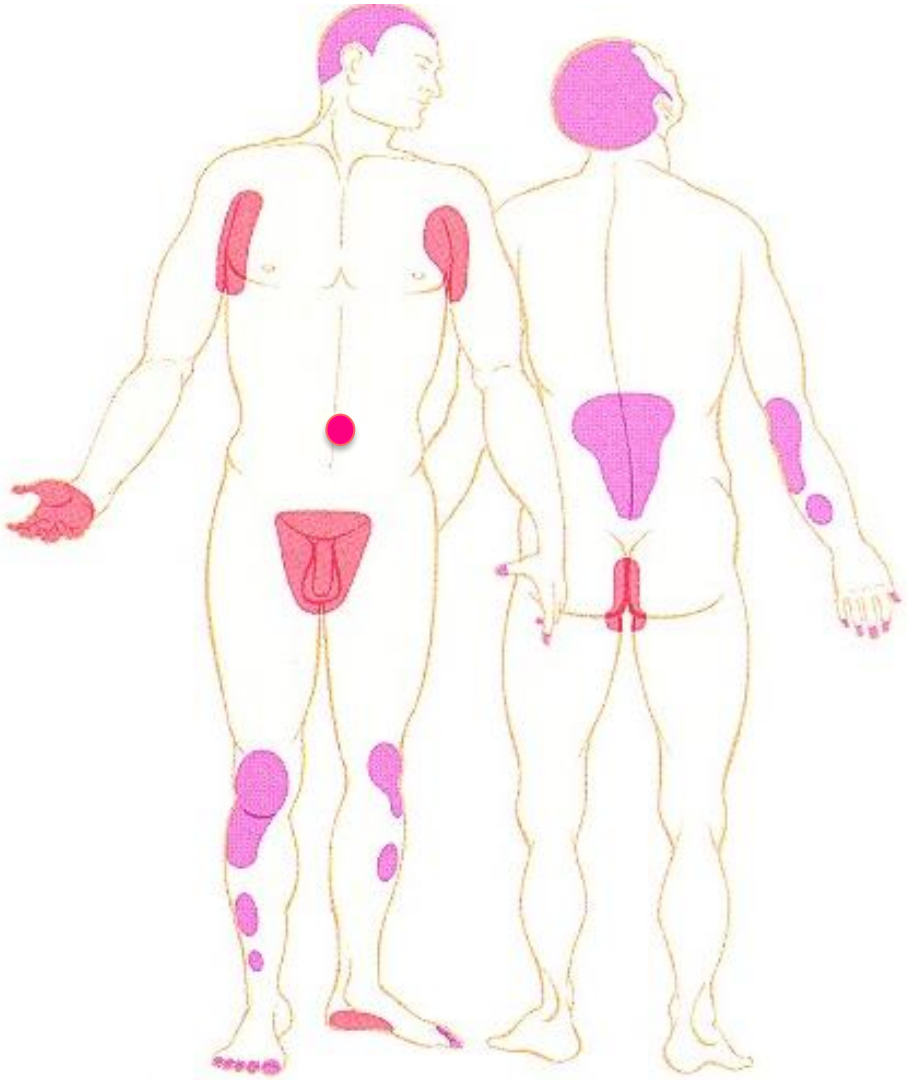

Seborrhoisches Ekzem

Klinik: gelblich-fettende Schuppung auf gerötetem Grund, Seborrhoe in der „Seborrhoische Areale“ -> Augenbrauen, Nasolabialfalte, Retroaurikulär, vordere und hintere Schweissrinne, Bauchnabel und Intimbereich

Prädispositionssfaktoren: Malassezia furfur, stress, HIV (extensive form!), Parkinson, Klima

Therapie: ketoconazole, ciclopirox

Seborrhoisches Ekzem



activ ingredient

excipient

In dermatology the excipient is as important as the activ ingredient!

Formulation

Solutions: are often powders that are dissolved in water or alcohol.

Gels: are a water or water-alcohol solution with refreshing properties.

Lotions: consist of suspensions or solutions of medication in water or alcohol. They provide a cooling and drying effect.

Creams: are semisolid emulsions of 20 to 50 percent oil in water.

Ointments: excellent lubricant, generally the most potent formulations due to their occlusive effect, but low acceptance/adherence.

The importance of the formulation

wet is treated wet

dry is treated dry

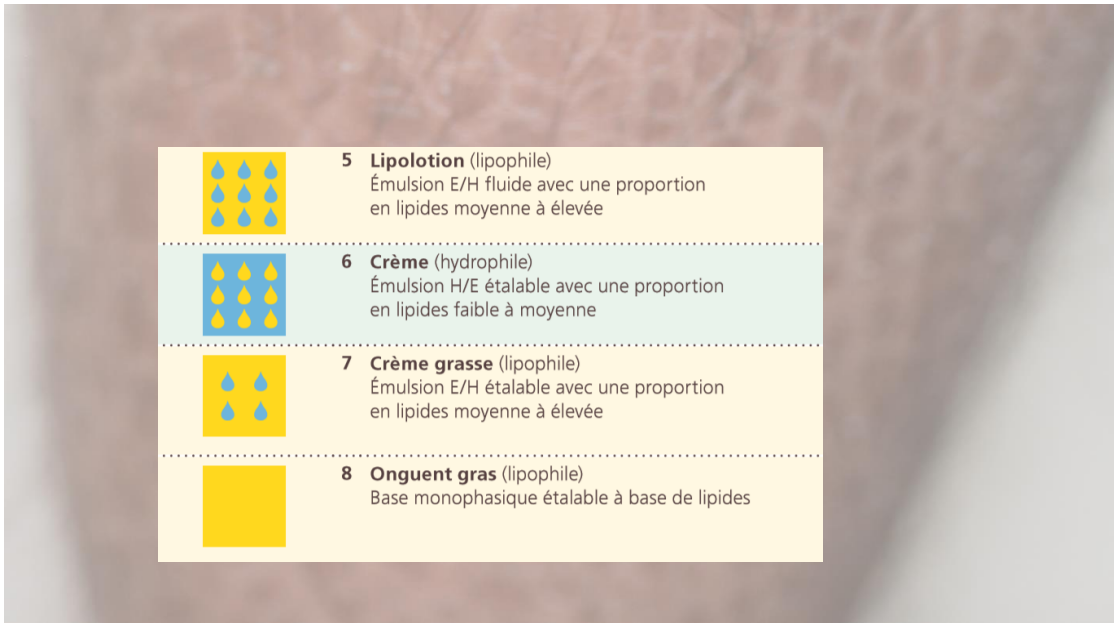

Lichen sclerosus

- Principal sign: Itch
- Mostly ano-genital involvement

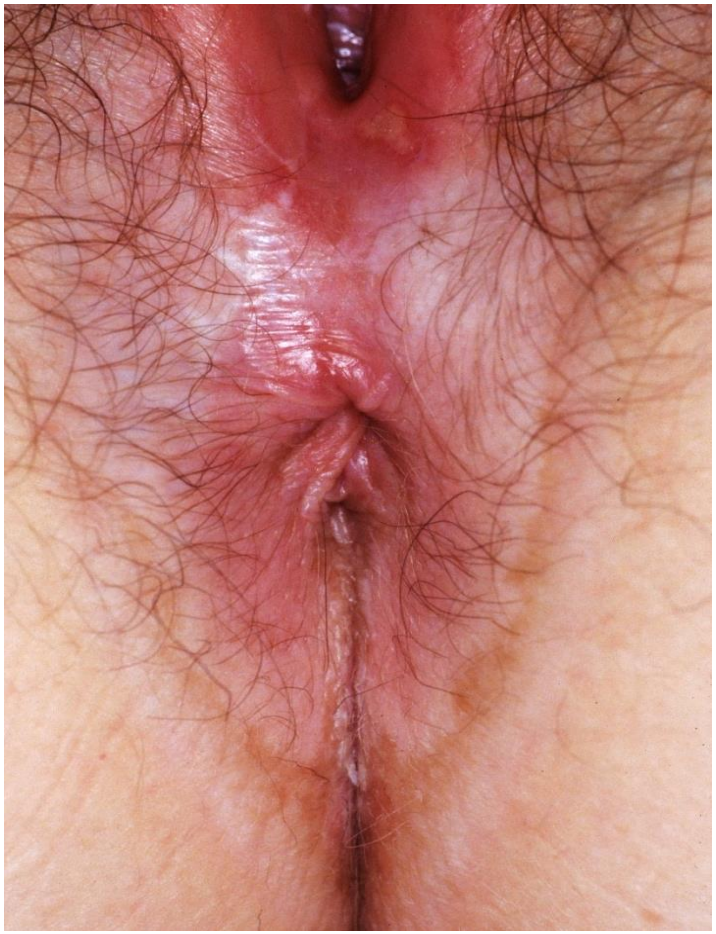

Mit freundlicher Genehmigung von Prof. Dr. S. Lautenschlager

Stadt Zürich
Stadtspital Triemli

eoc

Lichen sclerosus: Epidemiologie

- F>>M
- Any age but 2 peaks:
  - Childhood
  - After menopause
- Prevalence:
  - 1/30 postmenopausal women

Leibovitz A et al. Arch Gerontol Geriat 2000;31:1-4

Stadt Zürich
Stadtspital Triemli
eoc

Lichen sclerosus: Aetiologie

- Familial cases (HLA-DRB1*12)
- Autoimmune
  - Combined with thyroid dis., morphea, vitiligo
- Hormonal
  - Antiandrogenic drugs, HRTh
  - Turner syndrome

Brodrick B et al. Clin Dermatol 2013;31:780-6
Haidopoulos D et al. Diabetes Metab Case Rep 2016

Lichen sclerosus

- Importance of early diagnosis (scarring)
- Associated auto-immune disorders
- Risk of malignant degeneration
  - 4.5% (>10 years)